

Dermato-venereological Quiz

SM Wong 黃思敏, RCW Su 蘇志慰, ETY Cheung 張天恩

A 55-year-old woman presented with pruritic violaceous flat-topped papules and plaques over her legs for few years. She also complained of changes over her lips (Figures 1&2). She enjoyed good past health and denied any drug use. Histology shows features of lichen planus, including dense band-like lymphocytic infiltrate at

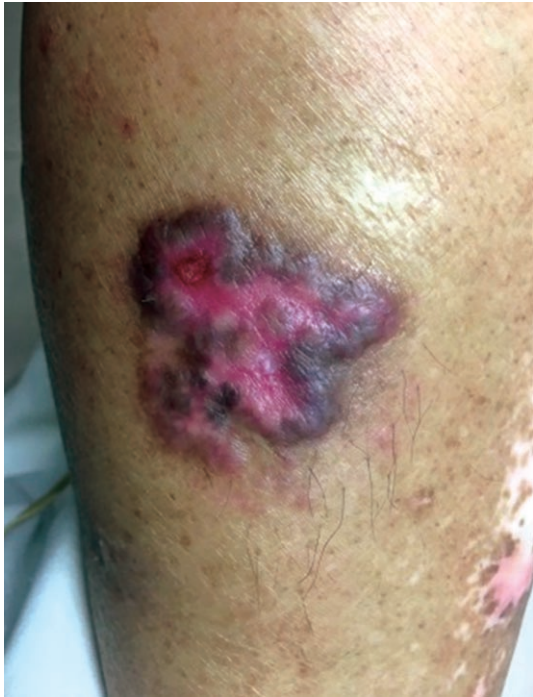

Figure 1. A violaceous plaque over left shin of the patient.

Social Hygiene Service, Department of Health, Hong Kong

SM Wong, FHKCP, FHKAM(Medicine)

RCW Su, FHKCP, FHKAM(Medicine)

Department of Pathology, Queen Elizabeth Hospital, Hong Kong

ETY Cheung, FHKCP, FHKAM(Pathology)

Correspondence to: Dr. SM Wong

Dermatology Division, Department of Medicine, Queen Mary Hospital, Pokfulam, Hong Kong

the dermal-epidermal junction and presence of apoptotic keratinocytes along the basal layer (Figure 3).

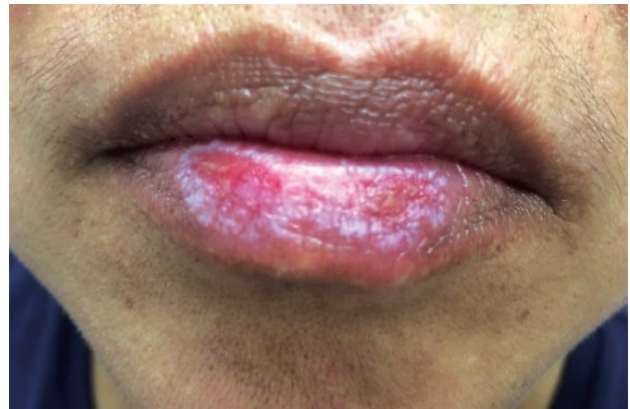

Figure 2. Lacy-white reticular lesions are shown on the patient's lower lips.

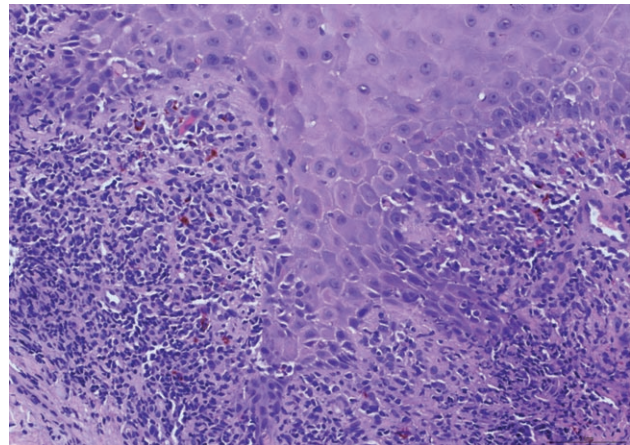


Figure 3. H&E stain 400x magnification.

Questions

1. What is the clinical diagnosis?
2. What are the typical histopathological findings for the disease?
3. What are the clinical signs that should be looked for in the oral cavity or genitalia?
4. What are the treatment options?

(Answers on page 94)