

Dermato-venereological Quiz

ECY Chu 朱灼欣 and WY Lam 林偉業

An 86-year-old male presented with a one year history of a hyperkeratotic plaque over the right middle finger. The lesion was non-itchy and non-tender, but had increased in size gradually (Figure 1). There was no previous history of trauma over the right middle finger and the rest of the skin was unremarkable. He had a history of minimal change glomerulonephritis, ischaemic heart disease and hypothyroidism. His drug history included prednisolone, azathioprine, thyroxine, aspirin, simvastatin, atenolol, perindopril and amlodipine. Skin scraping over the right middle finger for fungal culture was negative. A biopsy was done on the right middle finger (Figure 2).

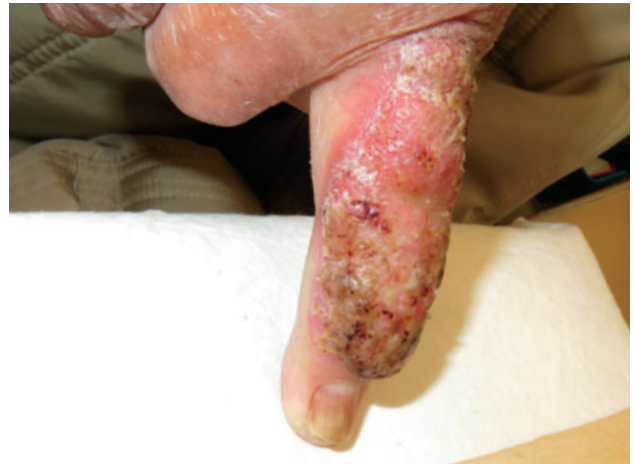

Figure 1. A hyperkeratotic plaque over the right middle finger.

Questions

- 1) What is the differential diagnosis?
- 2) What are the histological findings?
- 3) What is the diagnosis?
- 4) What are the treatment options?

Social Hygiene Services, Department of Health, Hong Kong

ECY Chu, FHKCP, FHKAM(Medicine)

Histopathology and Cytology Laboratory, Public Health Laboratory Centre, Department of Health, Hong Kong

WY Lam, MHKCPath

Correspondence to: Dr. ECY Chu

Wan Chai Social Hygiene Clinic, 7/F Tang Chi Ngong Speciality Clinics, 284 Queen's Road East, Wan Chai, Hong Kong

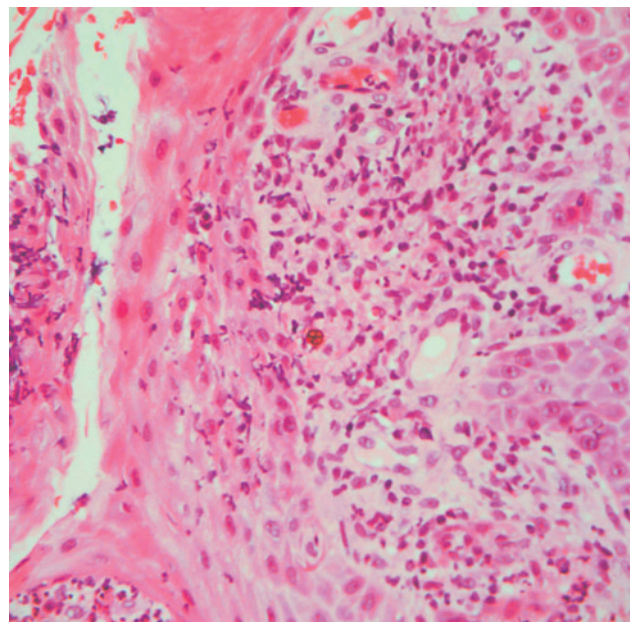


Figure 2. Sclerotic bodies and suppurative granulomatous inflammation (Haematoxylin-eosin stain; x 400).

(Answers on page 210)